

Fibrous dysplasia mimicking rib metastasis

DOI: <http://dx.doi.org/10.4321/S1889-836X2020000300006>

García-Gómez FJ, de la Riva-Pérez PA, Calvo-Morón MC
Nuclear Medicine Service. University Hospital Virgen Macarena. Seville (Spain)

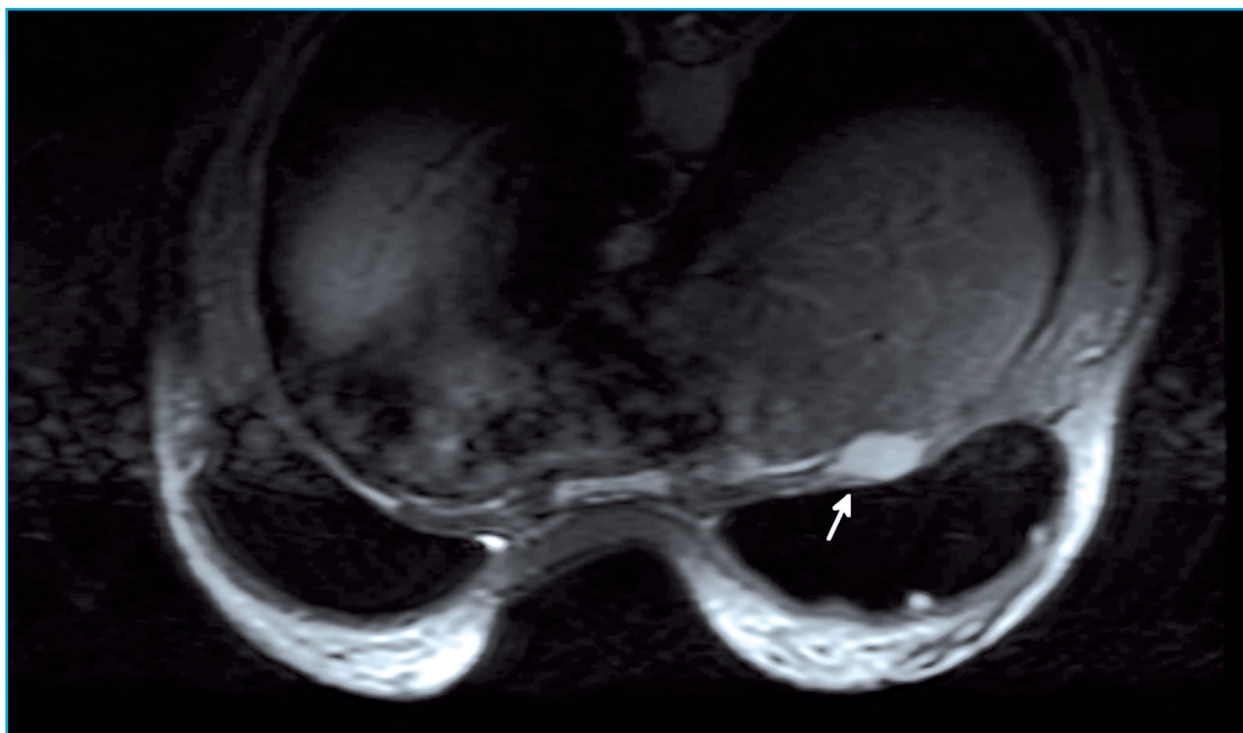
Date of receipt: 02/08/2020 - Date of acceptance: 15/09/2020

We present the diagnostic images of a 30-year-old woman, an asymptomatic BRCA1 mutation carrier and undergoing clinical-radiological follow-up for bilateral mammary fibroadenomas. The control MRI (Figure 1) highlighted the appearance of a nodular lesion posterior to the right breast prosthesis, relatively well defined and with lobulated contours. Given the suspicion of metastatic bone disease, a positron emission tomography (PET/CT) with 18F-fluorodeoxyglucose (18F-FDG) was carried out to assess its metabolic activity and extent of the disease. This was the only active lesion, with a 2.6 cm diameter and high metabolic activity, located in the fourth right costal arch (Figure 2). In this context, the lesion was excised to rule out neoplastic etiology. Patho-

logy studies showed it was fibrous dysplasia, a benign and slowly progressive pseudotumoral disease, which represents less than 5% of bone tumors.

Fibrous dysplasia is characterized by the replacement of normal bone tissue by osteofibrous connective tissue, adopting a sclerotic, cystic-lytic or mixed pattern^{1,2}. The disease is due to an imbalance in the function of osteogenic cells, triggering expansive osteolytic lesions that affect adjacent normal bone and fibrous tissue¹. The monostotic variant accounts for 70% of cases, and can be asymptomatic and detected incidentally². In monostotic forms, the bones most frequently affected are, in decreasing order, the maxillae, the proximal femur, the tibia, the humerus, the ribs, the skull, the radius and the iliac^{1,2}.

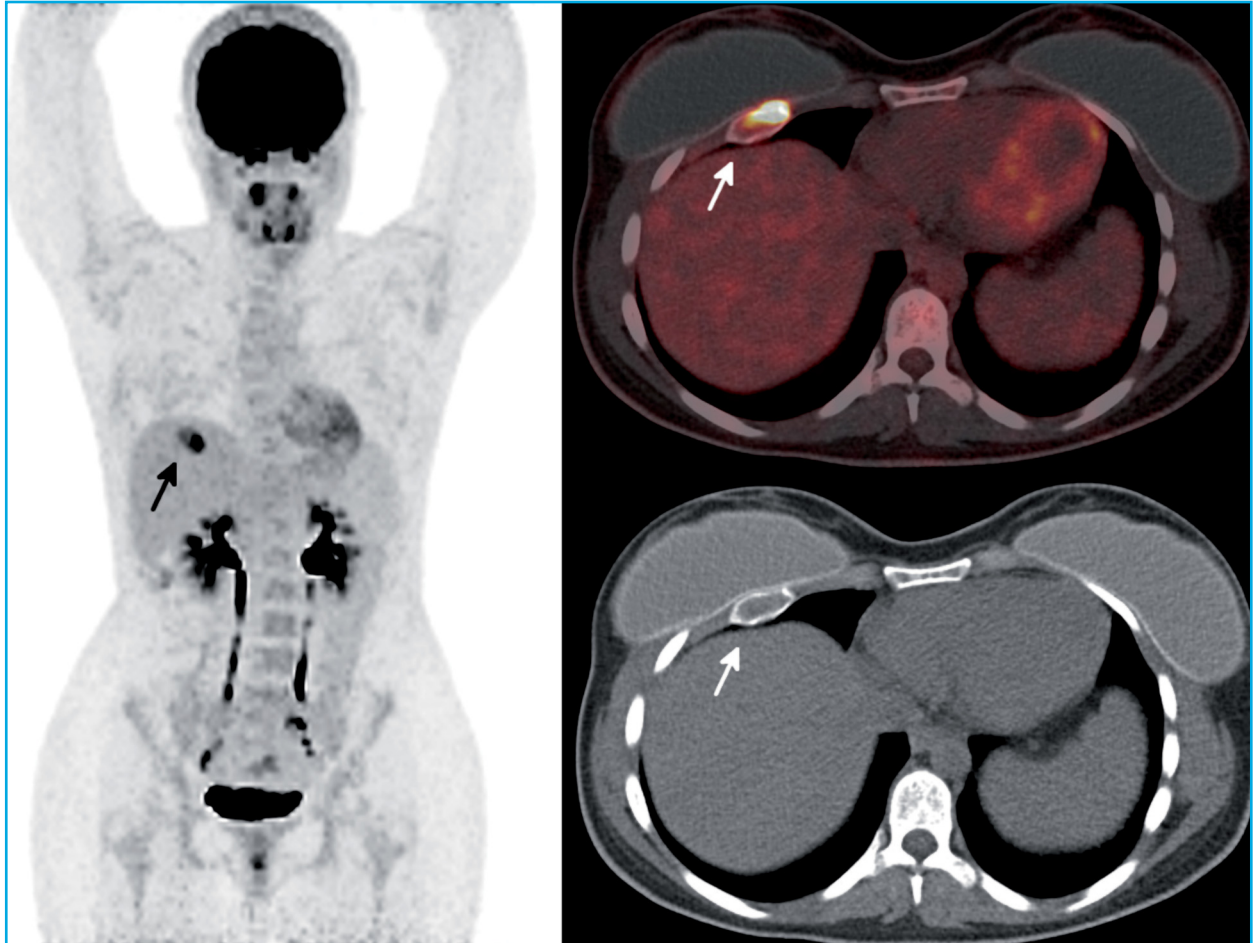
Figure 1. MRI showing nodular lesion in the right anterior thoracic wall (arrow), posterior to the breast prosthesis, with intense enhancement with contrast, intense rapid uptake and early lavage, compatible with a possible primary or secondary neo-formative nature, without ruling out other diagnostic options



In its diagnosis, diagnostic imaging techniques will be useful. As these lesions present a high rate of bone turnover, they will show high uptake in both bone scintigraphy and PET/CT, making them crucial techniques in the ob-

jective determination of the extension, metabolic activity and predicting the evolution of the disease^{3,4}. When there are doubts concerning the diagnosis, a bone biopsy or excision with mutational study may be carried out.

Figure 2. PET/CT with 18F-FDG, which highlights a single hypermetabolic lesion circumscribed to the anterior third of the fourth right costal arch (arrow), with very high metabolic activity (SUVmax:15.5)



▶▶ **Conflict of interests:** The authors declare no conflict of interest.

Bibliography

1. Lacoma Latre EM, Sánchez Lalana E, Bescós Marín JM. Fibrous rib dysplasia. *Med Clin (Barc)*. 2017;148(9):e51.
2. Florez H, Peris P, Guañabens N. Fibrous dysplasia. Clinical review and therapeutic management. *Med Clin (Barc)*. 2016;147(12):547-553.
3. Collins MT, Kushner H, Reynolds JC, Chebli C, Kelly MH, Gupta A, et al. An instrument to measure skeletal burden and predict functional outcome in fibrous dysplasia of bone. *J Bone Miner Res*. 2005;20:219-226.
4. Tuncel M, Kiratli PO, Gedikoglu G. SPECT-CT imaging of poliostotic fibrous dysplasia. *Rev Esp Med Nucl Imagen Mol*. 2012;31:47-48.